

3-Dimensional modeling to plan tricuspid valve in valve in a patient with a permanent dual-chamber pacemaker



Mirvat Alasnag, MD, Raed Sweidan, MD, Yousef Nosir, MD, Fayez Bokhari, MD, Khaled Al-Shaibi, MD

From the Cardiac Center-King Fahd Armed Forces Hospital, Jeddah, Saudi Arabia.

Introduction

In recent years, tricuspid valve in valve (TViV) procedures have been increasingly reported for inoperable individuals. The preprocedural evaluation is determined to a large extent on the type and size of the previously implanted prosthetic valve supplemented by imaging. In this case, the type and size of the valve were not known. Furthermore, the planning of the procedure was complicated by the presence of a dual-chamber pacemaker with a lead crossing the bioprosthesis into the right ventricle. Several options were considered, such as leaving the lead and risking damage to the insulation, placing a coronary sinus (CS) lead to pace her left ventricle, or implanting a leadless pacing system (Micra transcatheter pacing system; Medtronic, Minneapolis, MN). Imaging with transesophageal echocardiography and cardiac computed tomography were helpful in assessing the valve; however, we could not predict potential interactions between the proposed pacing strategies and the percutaneous transcatheter heart valve (THV) implantation based on imaging alone. Accordingly, a 3-dimensional (3D) model was printed and several in vitro simulations of the different strategies were tested on the printed model.

Case report

The patient is a 65-year-old woman who had implantation of a mechanical mitral valve and a bioprosthetic tricuspid valve in April 2007. Subsequently, in August 2007 she required placement of a dual-chamber pacemaker (Medtronic Adapta ADDR01) for complete heart block. A generator change was performed in 2014, at which time she was found to have chronic atrial fibrillation and her device was programmed to single-chamber pacing. She did well until 2019, when she had multiple admissions for right-sided heart failure,

KEYWORDS 3-Dimensional model; Dual-chamber pacemaker; Tricuspid valve in valve; Micra; Transcatheter heart valve implantation (Heart Rhythm Case Reports 2020;6:588–590)

All the authors have no conflicts to disclose. **Address reprint requests and correspondence:** Dr Mirvat Alasnag, Director of Catheterization Laboratory, King Fahd Armed Forces Hospital, Jeddah, Saudi Arabia. E-mail address: mirvat@jeddacath.com.

KEY TEACHING POINTS

- Complex percutaneous structural heart procedures require appropriate preparation and strategizing.
- 3D modeling can complement current advanced imaging modalities by offering a platform for in vitro procedural simulation.
- Collaboration across specialties permits the adoption of novel technologies and extending therapies to high-risk individuals with improved safety and better outcomes.

recurrent ascites, and pleural effusion, requiring pleurocentesis and abdominocentesis. Echocardiographic evaluation revealed a preserved left ventricular systolic function, ejection fraction 60%, severe degeneration of the tricuspid bioprosthesis with both severe stenosis and regurgitation, and a normally functioning mechanical mitral valve. She was assessed by the cardiac surgeons, who deemed her too high risk for a redo surgery given her obesity, chronic obstructive pulmonary disease, and limited mobility. Similarly, a lead extraction would entail general anesthesia and would not be considered a minimalistic approach. After discussion at the heart team meeting, she was evaluated for a percutaneous TViV. Cardiac computed tomography and fluoroscopy were used to determine the type and size of the degenerated tricuspid bioprosthesis (Figure 1 and Supplementary Figures S1 and S2). Although these imaging modalities provided vital information, they were not sufficient to determine the safest strategy for managing the right ventricular (RV) pacing lead, especially when considering she is pacer dependent. A 3D model was constructed to allow us to simulate the proposed pacing strategies. Specifically, the placement of a CS lead and its interaction with the Edwards Sapien 3 valve delivery system (Edwards Lifesciences, Irvine, CA) was evaluated (Figure 2). The simulation demonstrated a high probability of lead dislodgment during TViV

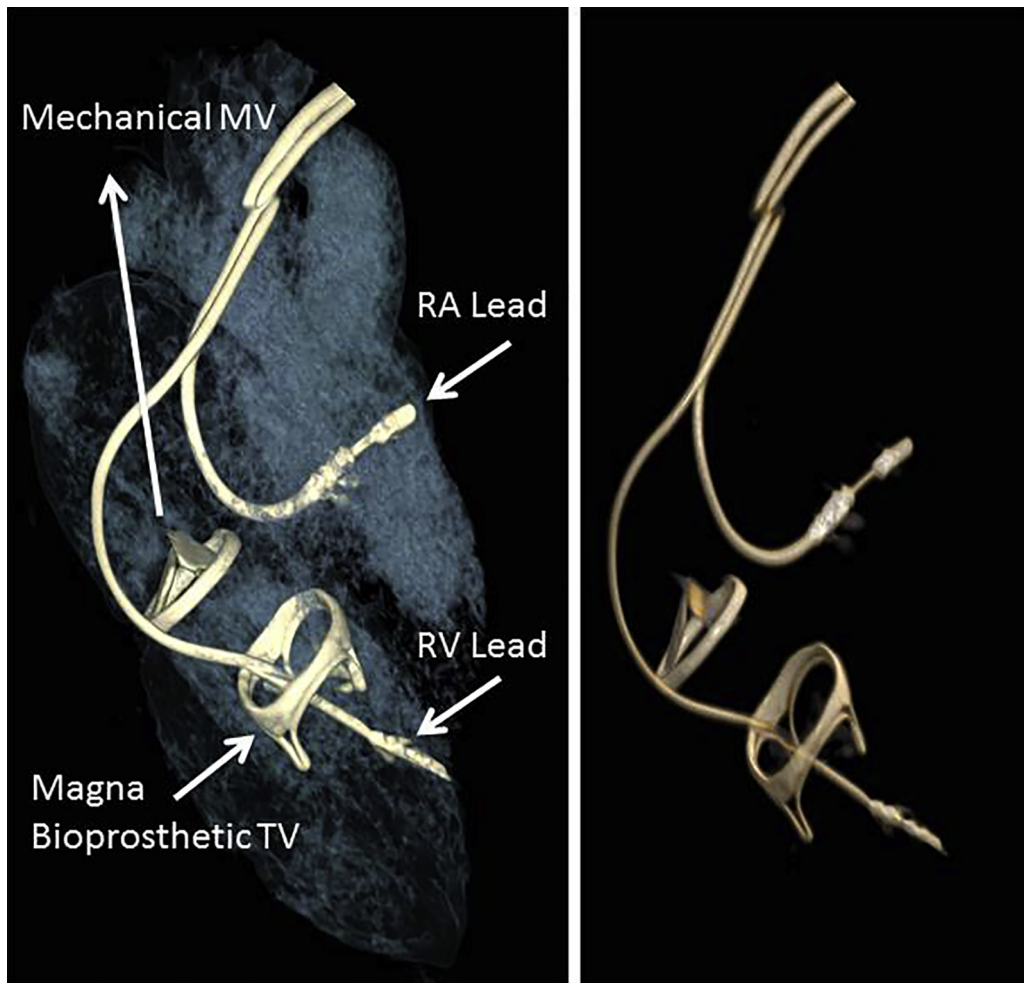


Figure 1 Cardiac computed tomography images: 3-dimensional volumetric reconstruction demonstrating the relationship of the tricuspid valve (TV) and mitral valve (MV) prostheses with the right atrial (RA) and right ventricular (RV) leads.

deployment. We therefore evaluated the feasibility of delivering a Micra device through the stenotic TV bioprosthesis, which was successful on the 3D model simulation. As such, the decision was to place a Micra transcatheter pacing

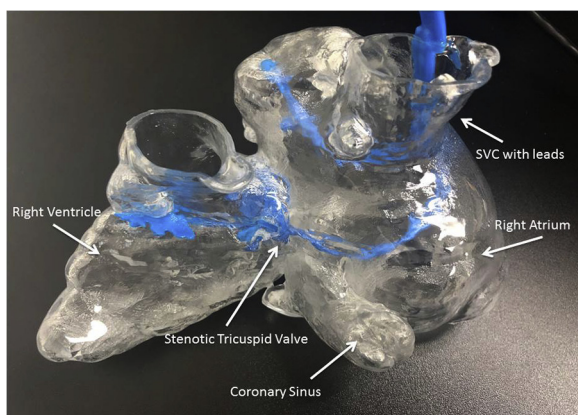


Figure 2 Three-dimensional printed model demonstrating the relationship of the tricuspid valve prosthesis, the right ventricular lead, and all the neighboring structures. SVC = superior vena cava.

system (Medtronic) followed by delivery of an Edwards Sapien 3 size 29 mm valve (Edwards Lifesciences).

The procedure was performed successfully and without complications. The previously implanted lead remained in place. Initially, a Micra delivery sheath was advanced through the right femoral vein over a 0.35 mm Extra Stiff Amplatz wire (Cook Medical, Bloomington, IN) to the mid right atrium using fluoroscopic guidance. The delivery catheter could be maneuvered successfully across the stenotic bioprosthesis, as had been simulated on the 3D model. The device was implanted at the apical septum in a stable position with satisfactory electrical parameters (all 4 tines secured, pacing threshold: 1.0 V at 0.24 ms, impedance: 700 ohms, R: paced). The mid septum was avoided to prevent possible dislodgment during the advancement of the balloon tip pulmonary artery (PA) catheter, which was demonstrated during the simulation. At this point, we proceeded with the THV implantation. The first step was to place the PA catheter across the degenerated TV and into the PA. This was a challenge and was only possible using a deflectable sheath (Agilis NxT steerable introducer; Abbott, Chicago, IL). Through this catheter, the 0.035 Extra Stiff Amplatz wire needed to

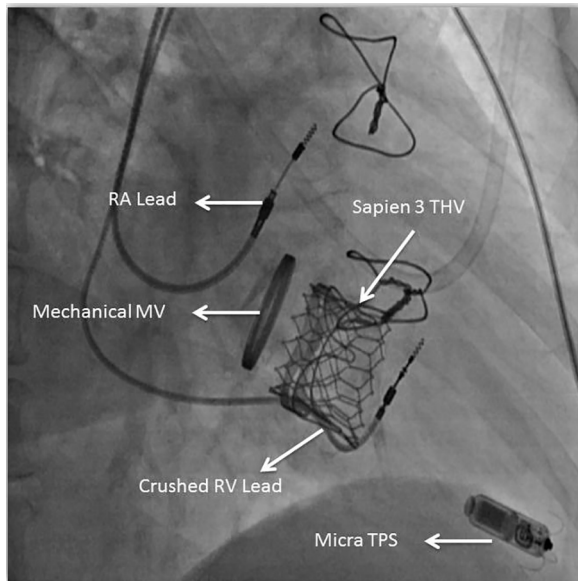


Figure 3 Fluoroscopic image post implantation of the Micra transcatheter pacing system (TPS; Medtronic, Minneapolis, MN) and the Edwards Sapien 3 transcatheter heart valve (THV) (Edwards Lifesciences, Irvine, CA) demonstrating the crushed right ventricular (RV) lead. MV = mitral valve; RA = right atrial.

deliver the THV was inserted. Subsequently, an Edwards Sapien 3 size 29 mm valve was successfully deployed (Figure 3). The results were confirmed by transesophageal echocardiography (Supplementary Figures S3 and S4). However, after the valve implantation, the RV lead was crushed and rendered nonfunctional. The Micra device remained in situ and device interrogation at the conclusion of the procedure confirmed excellent parameters.

Discussion

Although experience with TViV interventions has been steadily growing, performing such procedures in the presence of an RV lead remains uncommon. The key concern is damaging the RV lead, causing intraprocedural or late lead failure in a pacemaker-dependent patient. Upon review of the literature, limited reports on 3D modeling to guide management were available. One case report demonstrated survival of a pre-existing RV lead following a similar procedure; nevertheless, the follow-up was short and the patient was not pacemaker dependent.¹ In our patient, following the TViV implantation there was immediate RV lead failure and the patient was dependent on the Micra pacing system.

McElhinney and colleagues² reported that in their registry of 156 patients with TViV, only 24 had a preexisting transvenous right ventricular lead. The study does not indicate how many were truly pacemaker dependent. For a patient such as ours, epicardial pacing and lead extraction would entail general anesthesia, interruption of anticoagulation in a patient with a functioning metallic mitral valve prosthesis, and

opening of the pulse generator pocket, with a risk of bleeding, thrombosis, and infection. Similarly, the left ventricular retrograde pacing could be considered as a last-resort solution if right ventricular pacing could not be achieved given the potential thromboembolic risk associated with left ventricular endocardial pacing and the possible risk of introducing infection with opening and revising the pacemaker pocket. Moreover, the patient has a normal left ventricular function and did not develop symptoms of heart failure or left ventricular dysfunction even after more than 10 years of RV pacing.

This case underscores the importance of collaboration between the structural interventionalist and the electrophysiologist in defining the most appropriate treatment strategy for a complex intervention. A critical step in the success of the THV procedure was using the Agilis NxT deflectable catheter, which is more commonly used by electrophysiologists to deliver the PA catheter. Furthermore, simulation of the different strategies was greatly aided by the use of a 3D model that revealed several potential technical difficulties, namely, the dislodgment of a CS lead placed prior to the THV, the feasibility of crossing a stenotic bioprosthesis with a Micra delivery system, and interaction of a THV procedure with a septally implanted Micra pacing system. There are several case reports on the utility of 3D models, including a case report from our center highlighting the utility of 3D printing in the decision making in clinical practice.³

Conclusion

Contemporary catheterization laboratories offer a wide spectrum of complex procedures. Cross-specialty collaborative efforts allow us to improve current techniques as well as adopt new ones. Similarly, 3D modeling can contribute to the refinement of complex strategies by offering a platform for in vitro simulation. Both collaborative efforts and 3D modeling could potentially permit us to offer invasive therapies to high-risk individuals while maintaining safety.

Appendix Supplementary data

Supplementary data associated with this article can be found in the online version at <https://doi.org/10.1016/j.hrcr.2020.05.021>.

References

- Steinberg C, Dvir D, Krahn A, Webb J. Feasibility of tricuspid valve-in-valve replacement in a patient with transvalvular pacemaker. *HeartRhythm Case Rep* 2016;2:2–5.
- McElhinney DB, Cabalka AK, Aboulhossn JA, et al. Transcatheter tricuspid valve-in-valve implantation for the treatment of dysfunctional surgical bioprosthetic valves: an international, multicenter registry study. *Circulation* 2016; 133:1582–1593.
- Alasnag M, Al-Nasser I, Poqueddu M, Ahmed W, Al-Shaibi F. 3D model guiding transcatheter aortic valve replacement in a patient with aortic coarctation. *JACC Case Rep* 2020;2:352–357.